

**M E D I C A L   R E P O R T**

**ON**

**OF**

**39 BEAUFORT ROAD  
WROUGHTON  
SWINDON SN4 9HF**

**\*\*\*\*\***

**DATE OF BIRTH:**

**DATE OF INCIDENT:**      April 2012

**OCCUPATION:**

**TIME OFF WORK:**

**PREPARED BY:**              Mr Peter Revington, TD, BDS, MB,BS, FDS, FRCS (Eng)  
Consultant Oral & Maxillofacial Surgeon

**PREPARED FOR:**

**REFERENCE:**

**DATE OF REPORT:**          31.8.2012

**ADDRESS OF  
CONSULTATION:**              Frenchay Hospital, Frenchay Park Road, Bristol

**PHOTOGRAPHIC  
IDENTIFICATION:**

**DOCUMENTS AVAILABLE (1)  
FOR PREPARATION OF (2)  
MEDICAL REPORT: (3)**

**I confirm that I understand my duty to the court and have complied with it  
and will continue to comply with it and am aware of the requirements of  
Part 35 and Practice Direction 35, the Protocol for the Instruction of Experts  
to give evidence in civil claims 2005, as amended, and the practice direction  
on pre-action conduct**

## **CONTENTS**

	<b>Synopsis</b>	<b>Page 3</b>
1.	<b>Circumstances of Incident</b>	<b>Page 3</b>
2.	<b>Treatment</b>	<b>Page 3 - 4</b>
3.	<b>Progress of Symptoms</b>	<b>Page 4</b>
4.	<b>Past Medical History</b>	<b>Page 5</b>
5.	<b>Review of Records</b>	<b>Page 5 - 6</b>
6.	<b>Present State</b>	<b>Page 6</b>
7.	<b>Examination</b>	<b>Page 7 - 8</b>
8.	<b>Losses Consequential to Injury</b>	<b>Page 8</b>
9.	<b>Discussion</b>	<b>Page 9 - 11</b>
10.	<b>Recommendations</b>	<b>Page 12</b>
	<b>Appendix A – Glossary</b>	<b>Page 13</b>
	<b>Appendix B – Biographical Details</b>	<b>Page 14</b>
	<b>Appendix C – CV</b>	<b>Page 15 - 26</b>

## **SYNOPSIS**

.....underwent corrective facial surgery at....., ..... in April 2012. She experienced a range of perioperative problems, which resulted in her re-admission and which continued to cause her problems.

The purpose of this report is to identify the nature and extent of those problems and to establish, if possible, whether the care she received was commensurate with contemporary standards.

### **1. CIRCUMSTANCES OF INCIDENT**

In approximately 2007 .....was referred to .....with a view to undergoing corrective orthognathic surgery to correct her malocclusion.

She underwent a protracted course of orthodontic treatment in preparation for this surgery, although prior to her operation, at her request, she was transferred to the care of .....in ..... The reason for this transfer was that at the time of .....original referral no such service was available in ....., although clearly it is a centre closer to her home than .....

### **2. TREATMENT**

I understand that she met .....prior to her surgery and was admitted for a bimaxillary osteotomy to advance her maxilla and to reposition backwards

her mandible. This was carried out on the 26<sup>th</sup> April 2012. Both jaws were fixed in their new positions using titanium miniplates.

It appears likely that during the course of this operation, one of the orthodontic hooks, which was attached to .....orthodontic brace, became dislodged and fell into the surgical wound on her mandible on the left side. It seems probable that this was not noticed during the operation and the stainless steel hook remains insitu.

Although she was apparently unwell, she was discharged home the following day, but was re-admitted later in the day because of concerns expressed by her family and because she was becoming increasingly swollen in her face and body. She was re-admitted under the care of the general physicians on Friday, 27<sup>th</sup> April 2012 and was seen again by .....team on Monday, 30<sup>th</sup> April 2012 when the elastic bands, which had been placed prior to her discharge, were replaced. Following this .....condition improved and she was able to be discharged again on the 1<sup>st</sup> May 2012.

### **3. PROGRESS OF SYMPTOMS**

.....now tells me that she experiences intermittent swelling on the left side of her face. This is an almost daily occurrence and on average lasts for about 2 hours with each episode. The cause of this remains uncertain.

She also experiences altered sensation in the distribution of her left inferior dental nerve. This is a common complication associated with the type of surgery that ..... underwent.

#### **4. PAST MEDICAL HISTORY**

It is noteworthy that .....is believed to have a latex allergy, which was diagnosed approximately 10 years ago by her general medical practitioner as a result of a rash on her face.

#### **5. REVIEW OF RECORDS**

I have reviewed the record bundle provided for me, which includes the hospital and general medical practice records as well as a Witness Statement by .....sister. The most relevant of these are the hospital records, which contain correspondence tracing the history of ..... prior treatment at .....and her referral to ..... The records are all very unremarkable up to and including the record of her surgery carried out on the 26<sup>th</sup> April 2012. The operation note reveals a conventional surgical approach to her bimaxillary procedure and does not make any mention of the orthodontic hook, which was subsequently identified on her post-operative radiographs. I note also that at the time of her surgery it was planned to place elastics on the following day. This appears to have been carried out at 8.35 a.m. by one of the junior staff, ....., who identified the presence of the orthodontic hook on one of her post-operative radiographs. The case notes confirm that she was discharged following this review. The next entry by the Oral Surgery team dated the 30<sup>th</sup> April 2012 and follows a referral through the Accident & Emergency Department and a presumed anaphylactic reaction. At this stage it was not clear to which agent ..... had developed this reaction. She attended for several more review appointments, although the dates of these

have not been replicated in the photocopied records that I have seen. On the 1<sup>st</sup> May 2012 a further entry identifies that the elastic traction being used in ..... mouth, which had been placed post-operatively, contained latex. The record reads *“advised policy to be latex free but unfortunate that latex elastics were still available. Advised that they have been removed from the department and will be”... “non-latex elastics placed”*. I note from the case notes that there is also some discussion about the need to remove the orthodontic hook, which has been referred to above, and from the early part of May, I understand that at ..... request, she was followed-up by ....., Consultant Oral Surgeon at ..... She was seen early in May (date illegible) and also on the 10<sup>th</sup>, 24<sup>th</sup> and 31<sup>st</sup> May 2012 for review. At each of these visits she appears to have sequentially improved. There appears to be very little correspondence relating to these post-operative clinic episodes.

## **6. PRESENT STATE**

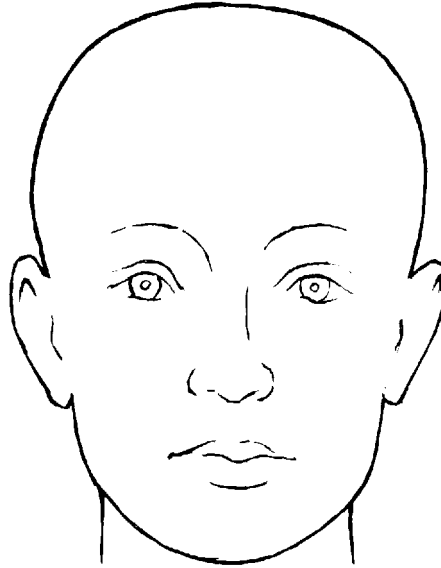
### **Symptoms**

..... now complains of the intermittent swelling on her face recounted above and also the numbness on the left side of her face.

She is also very concerned about the presence of the orthodontic hook in her wound on the left side.

## 7. EXAMINATION

### Extra-Oral Examination



.....is experiencing altered sensation in the distribution of her left inferior dental nerve. This is shown diagrammatically above. This is a common consequence of the type of surgery that she underwent and I would expect this to recover slowly over the course of 6-12 after her surgery. Recovery is not always complete.

..... tells me that she is experiencing an occasional burning sensation on this side of her face and it is conceivable that this represents an element of hyperaesthesia, which frequently accompanies nerve recovery.

I have also reviewed ..... post-operative radiographs. On the panoramic radiograph taken in ..... in April 2012 an orthodontic hook is visible at the left angle of her mandible.

**Intra-Oral Examination**

On intra-oral examination ..... had the following teeth present:-

RIGHT	<u>654321/123456</u>	LEFT
	7654321/1234567	

..... has a Class I incisor relationship and a good occlusion and a pleasing profile as a result of her surgery.

Her pre-operative radiographs show the orthodontic appliances in place and demonstrate that she had a marked Class III dental base relationship with a reverse overjet of approximately 7mm.

**8. LOSSES CONSEQUENTIAL TO INJURY**

I understand that ..... has not fully enumerated her incidental losses. I have suggested that she discuss these with her legal representatives.



## 9. DISCUSSION

In discussing the events surrounding Tina-Louise's surgery and her subsequent re-admission it is clear that there are a number of issues with which she has concerns. These may be enumerated as follows:-

- (a) The retention of an orthodontic hook within the wound on the left side of her face.
- (b) The development of an apparent anaphylactic reaction ? to latex as a result of the use of latex containing elastics post-operatively.
- (c) Failure of communication.

I will deal with each of these in turn.

### ***Retention of the orthodontic hook within the wound***

In general terms it is always undesirable to leave foreign bodies within patients' wounds. I am certain that if the surgeon concerned had been aware that a hook had become dislodged and retained within the patient's wound, every effort would normally have been made to remove it. The failure of an orthodontic hook of this type is, I believe, an extremely rare event. I myself have carried out in excess of 300 such procedures and have never experienced a similar failure. I am not aware of any case reports of this in surgical literature.

The orthodontic hooks are made of stainless steel and are placed on the orthodontic wires (braces) in order to facilitate the placement of the jaws in their correct position during surgery. They are very small, no more than a few mm in length. In the event that the surgeon became aware that one of these had become lost in the patient's soft tissues during the operation as stated above, it would be normal practice to attempt to remove it. However, in the event that this proved difficult because of visibility due to bleeding and the small size of the hook itself, then I think it likely that most surgeons would elect to leave the hook insitu confident in the knowledge that their small size and bio-compatibility would render it extremely unlikely that the patient would experience any difficulties as a result. It is conceivable that patients would experience greater morbidity as a consequence of strenuous efforts to find such a foreign body if this were not immediately obvious.

**? Latex Allergy**

..... tells me that her latex allergy was known to the hospital staff at the time of her surgery and she wore a medic alert bracelet to this effect. She tells me that after her latex containing elastics were removed her general condition improved and she was able to go home. I understand also that she has never been formally tested against latex and it is conceivable that the anaphylactic reaction, which she experienced, was related to the antibiotics she was given at the time of her surgery and not to latex.

In the event that a patient, known to be allergic to latex developed an anaphylactic reaction as a result of coming into contact with latex during their surgery, then it is my view that this would be deemed to be negligent. No

competent cohort of contemporary clinicians would knowingly expose a latex allergic patient to latex. This does appear to have occurred during ..... management in that the elastics that were placed in her mouth following her surgery did seemingly contain latex and after they were changed for latex-free elastics her condition appears to have improved.

*It is not known however that the anaphylactic reaction, which she experienced, was due to the latex exposure and not to an allergy to one of the antibiotics that was prescribed for her.*

***Failure of communication***

From what ..... tells me, subsequent to her re-admission there appears to have been a failure to communicate with the maxillofacial team and to discuss adequately her case and this may have in part led to an apparent breakdown of the relationship between ..... and ..... However, this is not clearly reflected in her case notes and I am not therefore able to comment upon it.

It is apparent from the case notes that ..... was exposed to latex containing elastics, which she wore intraorally for a number of days. On the balance of probabilities it seems likely that it was to these that she developed the reaction that resulted in her facial swelling and necessitated her re-admission to hospital rather than to the antibiotics to which she had no previous history of allergy.

## 10. RECOMMENDATIONS

In view of the continued and unexplained symptoms, which ..... experiences, I think that it would be desirable for her to undergo a series of patch tests to establish her allergy status to a range of metals including stainless steel to exclude the possibility that some of her on-going symptoms relate to the presence of a retained orthodontic hook. It is unlikely that the physical presence of this hook would account for her symptoms unless she is in some way allergic to it. It would also be useful to confirm her latex allergy and possibly exclude the possibility of a Penicillin allergy as an explanation for the symptoms that led to her re-admission after her operation.

I also feel that an expert medico-legal report by a dermatologist or similar professional specialising in the study of allergy might add some value.

**I confirm that I have made clear which facts and matters referred to in this report *are within* my own knowledge *and which are not*. Those that are within my own knowledge *I confirm* to be true. The opinions I have expressed represent my true and complete professional opinions on the matters to which they refer**

**PETER REVINGTON, TD, BDS, MB, BS, MScD, FDS, FRCS (Eng)**  
Consultant Oral & Maxillofacial Surgeon

## APPENDIX A

### GLOSSARY

#### **Hyperaesthesia**

In contrast with anaesthesia, hyperaesthesia refers to **increased** sensitivity or sensation. It is occasionally a sign of recovery of nerve function following damage.

#### **Occlusion**

A term which describes the “*normal*” way in which the teeth interdigitate.

#### **Osteotomy**

A surgical procedure to fracture and reposition a bone. In this case the mandible is split in the sagittal plane, allowing it to be moved, either forwards or backwards, to a predetermined position. This position is usually dictated by the construction of a plastic wafer, which fits between the teeth at operation to enable the surgeon to reliably place the jaw in the desired position.

#### **Orthodontic Treatment**

The application of forces to a tooth, to cause it to move through its supporting bone, while remaining firm in its socket.

## **APPENDIX B**

### **BIOGRAPHY**

I am a Consultant Maxillofacial Surgeon with the qualifications, BDS, MB,BS, MScD, FDS, FRCS (Eng). My higher surgical training was carried out at Charing Cross, St. Thomas's Hospital and King's College Hospital, London. I was appointed as a Consultant Oral & Maxillofacial Surgeon at Frenchay Hospital, Bristol in December 1994.

I specialise in the treatment of patients with severe facial trauma and have an interest in salivary gland disease, temporomandibular joint dysfunction and facial reconstruction.

**APPENDIX C**

**CURRICULUM VITAE**

**Peter John Revington**

---

## CURRICULUM VITAE

### PERSONAL DETAILS

Name Peter John Revington

Work Mobile: 07885 107646  
Dept. of Maxillofacial Surgery,  
Frenchay Hospital,  
Frenchay Park Road,  
Bristol  
BS16 1LE  
Tel: 0117 3403997  
Fax: 0117 3406650

E-mail: peter.revington@nbt.nhs.uk

Web site: www.MrPRevington.co.uk

Date of Birth 29/12/53

Place of Birth St. Andrews, Fife

Nationality British

Marital Status Married: two children

### EDUCATION

School 1966 - 1972 Kingswood School,  
Lansdown, Bath

University 1972 - 1976 University of Wales Dental  
School, Heath Park, Cardiff

1986 - 1991 Charing Cross & Westminster  
Medical School

### QUALIFICATIONS

University 1976 B.D.S (Wales)  
1991 M.B., B.S. (U. London)

Postgraduate 1980 MScD (Wales)  
1981 FDS RCS (England)  
1993 FRCS (England)

### ACCREDITATION DATE

1/1/94

### GMC NUMBER:

3555486

### GDC Number

49934

### MDU Number

124763F expires 9/12



**SPECIALIST REGISTRATION:**

Specialist listings for:

Maxillofacial Surgery  
Oral Surgery

**PRIZES AND DISTINCTIONS**

1975  
1975

Freda Berg Prize (Oral Biology)  
Distinction Oral Biology (4th  
BDS)

1987  
1990

Anatomy Dissection Prize  
Forensic Medicine Project Prize

**DECORATIONS**

Territorial Decoration 1998  
Queens Jubilee Medal 2002  
Campaign Medal (Afghanistan)  
2007

**POSITIONS HELD**

**NHS Posts 1976-1982**

Jul. 1976 - Feb. 1977	HS Oral Surgery Cardiff Royal Infirmary,	
Feb. 1977 - Jun. 1977	Community Dental Officer	Kent AHA Dartford
Jun. 1977 - Jul. 1978	SHO Oral Surgery	Royal United Hospital Bath
Sep. 1978 - Sep. 1979	MRC Training Fellow	Dental School Cardiff
Oct. 1979 - Jan. 1982	Registrar, Oral Surgery	Bristol Royal Infirmary Frenchay Hospital/ Bristol Dental School

**ROYAL ARMY DENTAL CORPS January 1982 - October 1986**

Rank attained: Lt.Col

Jan. 1982 - Mar. 1983	Senior Specialist (Senior Registrar) Oral Surgery	Duchess of Kent Military Hospital / Cambridge Military Hospital Aldershot
Jan. 1983 - Mar. 1983	Royal Military Academy	Sandhurst
Apr. 1983 - Apr. 1985	Senior Specialist Hospital (Senior Registrar)	British Military Rinteln, West Germany
Apr. 1985 - Oct. 1986	Honorary Senior Registrar	Charing Cross & St. Thomas's Hospitals
Apr. 1985 - Dec. 1986	Honorary Clinical Teacher	Charing Cross & Westminster Medical School

**NHS POSTS 1991-**

Aug. 1991 - Feb. 1992	House Physician (Gastroenterology / Endocrinology)	Charing Cross Hospital
Feb. 1992 - Aug. 1992	House Surgeon (General / Orthopaedics)	West Middlesex Hospital
Aug. 1992 - Aug. 1993	Senior House Officer (General Surgery)	Kingston Hospital
Aug. 1993 - Nov 1994	Senior Registrar Maxillofacial Surgery	Kings College Hospital
<b>Dec. 1994-</b>	<b>Consultant Maxillofacial Surgeon</b>	<b>Frenchay Hospital Bristol</b>
<b>June 2004-</b>	<b>Cleft Surgeon (with an interest in secondary surgery) 5 sessions</b>	<b>SW/ Wales Cleft Network</b>
May 1997-Feb 2000 & Sept '02-	Speciality director	

### **COURSES ATTENDED**

Feb 1997	Training the Trainers- Royal College of Surgeons
June 1997	Facial Aesthetic Surgery Course North Wales
June 1998	Facial Aesthetic Surgery Course 2. North Wales
July 1999	Nice. Health Services Management Centre, Birmingham
October 1999	Salivary Gland Symposium. St Thomas' Hospital
March 2001	Appraisal & Assessment RCS England
Nov 2001	Clinical Audit Conference, Edinburgh
Nov 02	Excellence in report writing, London
Nov 02	Definitive Surgical Trauma Skills, RCS, London
Nov 05	Intermediate Life Support course
Oct 10	Power & Politics in the NHS Baroness Cumberledge, Severn Deanery

### **PUBLICATIONS**

1. Thesis: "The cytotoxic potential of cementum bound endotoxin" (University of Wales 1980)
2. Turret Exostosis - a case report. **Revington P.J**  
Presented to BAOS Autumn meeting 1981  
British Journal of Oral Surgery 1984; **22**: 37-41.
3. Temporomandibular joint dysfunction - a case of hysterical trismus.  
British Dental Journal 1985; **158**: 55  
(**Revington**, Kingscote & Peacock)
4. The Dautrey Procedure - a case for reassessment. **Revington P.J**  
British Journal of Oral and Maxillofacial Surgery 1986; **24**: 217-220.
5. Metastatic Thyroid Carcinoma: An Unusual Presentation.  
British Journal of Oral and Maxillofacial Surgery 1989; **27**: 341-345  
(**Revington** & Morgan)
6. Lyme Disease: A Deer Survey in Richmond Park.  
Deer 1990; **8**: 30 -31  
(**Revington**, Wright & Cutler)
7. Testicular Sarcoidosis, A Case Report. **Revington PJ**  
British Journal of Urology 1994; **73**: 596-597
8. The Economics of Knot Tying Techniques.  
Annals of the Royal College of Surgeons of England (Suppl) 1994;**76**: 281  
(**Revington** & Bowyer)

- 
9. A review of 23 patients with tuberculosis of the head and neck. (Presented at BAOMS Autumn meeting 1994.)  
**Penfold C & Revington P**  
British Journal of Oral & Maxillofacial Surgery 1996; **34**: 508-510
  10. Age Determination in Deer. **Revington P**  
Deer 1996;**10**: 20-21
  11. Local anaesthesia: to warm or alter the pH? A survey of current practice.  
J R Coll. Surg. Edinb 1999; **44**: 167-171  
(Courtney DJ, Agarwal S, & **Revington P**)
  12. Magnetic Resonance Imaging of Parotid tumours: Poster presentation  
BAOMS Birmingham 1999 (Courtney, D. Morse, M. Raja, M & **Revington P**) Abstract:  
British Journal of Oral & Maxillofacial Surgery 1999; **37**: 236
  13. The Proximal Tibia donor site in Cleft alveolar bone grafting: experience of 75 consecutive cases. Hughes C. & **Revington P. J.** Craniofacial Surgery 2002; **30**: 12-16
  14. Extracranial Fasciitis in childhood: A sheep in Wolves clothing? Hughes C. **Revington P.** Berry R & Saunders M. British Journal of Oral & Maxillofacial Surgery 2002; **40**: 341-343
  15. Custom-made titanium orbital floor prosthesis in Reconstruction for orbital floor fractures. Hughes C. **Revington P.** Page K. & Bibb R.  
BJOMS 2003 **41**: 50-53
  16. 'Ticks & Lyme Disease' Advice note No 3, Published by the Deer Initiative 2004
  17. 'Outside the Comfort Zone' **Revington P.J** British Medical Journal 2007 **335**: 502
  18. Anterior cranial Fossa Dermoid Cyst: Case Report  
Blythe J, **Revington P**, Nelson R  
BJOMS 2007 **45**: 661-663
  19. Is there an epidemic of admissions for surgical treatment of dental abscesses in the UK?  
Thomas, SJ. Atkinson C. Hughes, C. **Revington P.** Ness, A.  
British Medical Journal 2008;**336**:1219-1220
  20. Superficial Parotidectomy: antegrade compared with modified retrograde dissections of the facial nerve.  
K Anjum, **PJ Revington**, G Irvine  
BJOMS 2008, **46**: 433-435
  21. Bilateral ankylosis of the jaw treated with total alloplastic replacement using the TMJ concepts system in a patient with ankylosing spondylitis. Manemi R, **Revington PJ**, Fasanmade A.  
BJOMS 2009, **47**: 159-161

22. Guo C, Shi Z, **Revington P**. Arthrocentesis and lavage for treating temporomandibular joint disorders. *Cochrane Database of Systematic Reviews* 2009, Issue 4. Art. No.: CD004973. DOI: 10.1002/14651858.CD004973.pub2.
23. Novel use of an aerospace selective laser-sintering machine for rapid prototyping of an orbital blowout fracture.  
Williams J.V, **Revington PJ**  
*International Journal of Oral & Maxillofacial Surgery*  
2010 **39**: 182-184
24. Sudden Hypotensive Syncope and Significant Iatrogenic Maxillofacial Trauma, following administration of sodium phosphate purgative solution.  
Williams J, Colbert S & **Revington P**. *Journal of Perioperative practice*.  
2010 **20**: 181-180
25. Low Grade marginal zone B-cell lymphoma presenting as local amyloidosis in a submandibular salivary gland.  
Pereira, E., **Revington, P.** & Sheffield, E.  
*International Journal of Oral & Maxillofacial Surgery*  
2010, **39** 1136-1138
26. "The Outcome for Secondary Alveolar Bone Grafting in the South West UK Region Post CSAG" Felstead A., **Revington P.** & Deacon, S. *Cleft Palate & Cranio-facial Journal*. 2010 **47**: 359-62
27. Alveolar Bone Grafting: Results of a National Outcome Study.  
**Revington P.**, Deacon, S. Shah, H, Macnamara C & Pereira E  
*Ann R Coll Surg Engl* 2010; **92**:643-686
28. Amaurosis, ophthalmoplegia, ptosis, midriasis and periorbital blanching following inferior alveolar nerve anaesthesia.  
Williams, J. Williams, L. Colbert, S. & **Revington P**  
*Oral Maxillofacial Surg* June 2010 (DOI 10.1007/s10006-010-0238-5)
29. Facial basal Cell Carcinoma in a Young Crohns disease patient.  
Williams J., & **Revington P.**  
*J Craniofacial Surg* **21**: 2010 DOI: 10.1097/SCS.0b013e3181f504c4
30. Surgical Management of Temporomandibular Joint Ankylosis in Ankylosing Spondylitis. Felstead A, & **Revington PJ**  
*Int. J. Rheumatol*, 2011 vol. 2011, Article ID 854167, 5 pages, 2011.  
doi:10.1155/2011/854167.
31. Eagles Syndrome: A Novel Surgical Approach to the Styloid Process Using a Pre auricular Incision.  
Williams, JV, McKEarney, R, & **Revington PJ.**  
*J.Oral Maxillofac Surg* 2011 Jun;69(6):1617-22. Epub 2011 Mar 21

32. Maxillofacial Trauma Experience for OMFS Registrars since Calman and implementation of the European Working Time Directive: A comparison of Surgical Experience and Aetiology in 1980 and 2010. Nandra, B Shah K. Felstead A. & **Revington PJ**  
Ann R Coll Surg Engl 2011 Accepted for publication

### **BOOKS**

Maxillofacial Injuries: in 'The British Military Surgery Pocket Book'.  
Crown Copyright 2004 (AC 12552)

#### **Presentations**

Magnetic Resonance Imaging of Parotid Tumours  
Presented at 'Stomatology 2000', Moscow, Feb 2000

TMJ Prosthesis- One patient's Twenty Year Perspective.  
European TMJ Study Group, Birmingham May 2008

Alveolar Bone Grafting: Results of a National Outcome Study  
Craniofacial Society Conference Belfast 2009

Outside the Comfort Zone  
Royal Society of Medicine May 2011

#### **Posters**

Magnetic Resonance Imaging of Parotid tumours: Poster presentation  
BAOMS Birmingham 1999 (Courtney, D. Morse, M. Raja, M & **Revington P**)

Jaws, Are you Afraid? UK Radiology Conference, Manchester 2007  
Dr M A Hanif, **Mr P Revington**, Dr S.Gandhi

Bilateral TMJ Ankylosis treated with TMJ concepts Prosthesis  
Manemi, Fasanmade, K., & **Revington P.**  
18<sup>th</sup> International Conference on Maxillofacial Surgery, Bangalore India 2007

The design of a clinical trial on the timing of surgical repair of cleft lip and  
palate. SD Colbert, **PJ Revington** & MJ Evans  
BAOMS Conference Bournemouth 2009

Penetrating orbitocranial injury with wooden foreign body: radiological  
characteristics and clinical sequelae  
Kumar Abhinav; A. Amit; **P. J. Revington**; N.R. Patel, V. Iyer  
Society of British Neurosurgeons Conference 2011

An Unusual Presentation of Hyperglobus  
De Gea Rico A, Parmar S, **Revington PJ.**  
BAOMS JT Conference 2011

#### **Letters**

Courtney D, & **Revington P.** Local Anaesthesia  
JR Coll. Surg. Edinb 1999; **44**: 278

---

**Professional Bodies**

British Medical Association

British Association of Oral & Maxillofacial Surgery

Craniofacial Society

**EDUCATIONAL WORK**

**Regional Advisor (S.West)** Royal College of Surgeons of England  
2006-

**Regional Training Programme  
Director (Severn Deanery)** 2009-

**Postgraduate Dental Tutor** University of Bristol 1996 - 2002

**Postgraduate Dental Tutor** Royal College of Surgeons (Eng) 1996-1998

**Hon Senior Lecturer** U. Bristol 1997-

**Examiner** U.Bristol 2006-

**Examiner, Intercollegiate Specialty Board** 2009-

**Organiser** Minor Oral Surgery Course for GDPs  
1995/6/7/9

Organiser Annual Regional SHO Induction  
course 1995-2007

BATLS Instructor 1996-2003  
(Battlefield Advanced Trauma Life Support)

**Member** SW. Postgraduate Dean's Advisory Panel  
2000-2006

Hospital Recognition Committee (Visitor)  
Royal College of Surgeons of England  
2003-2006

Of Faculty: MOST Course (Military  
Operational Surgical Trauma) RCS Eng

**Director and faculty** Maxillofacial skills Workshop Centre for  
Defence Medicine, Birmingham 2002-(twice  
annually)

'Emergencies in Maxillofacial Surgery'  
Royal College of Surgeons of England 21-  
22/7/04 & 2005

**Elected Bodies** Craniofacial Society of Great Britain  
Elected to Audit group 2005  
(Chairman 2007-2010)

BMA Armed Forces Cttee 2008/9  
2009/10/11

**COMMITTEE WORK:**

Member: Regional Professional Affairs Board 2012-

Member BAOMS Clinical Effectiveness Ctte 2011-

Member: Trust Management Team, 1999-2001

Member: Frenchay Hospital Clinical Audit Committee 1995- 97

**Chairman.** Frenchay Hospital Clinical Audit Committee 1997-1999

**Chairman.** North Bristol Trust Clinical Audit & Clinical Effectiveness Committee 1999-2005

**Chairman,** Frenchay Hospital Consultants Advisory Committee 1999-2001

Member: Clinical Risk sub Group, Frenchay Hospital 1997- 2005

**Secretary,** South West BDA Hospitals Group 1995-1998

Member of Council, Bristol Section BDA1997-98

Elected Member Craniofacial Society Audit Group 2005-6

**Chair:** Craniofacial Society Audit Group 2007-

Member: Avon Dental Advisory Committee1997-2004

Member: **BMA** Armed Forces Committee 2008/9/10/11

Member: **BDA** Armed Forces Committee 2009

**BAOMS**

BAOMS Audit lead for SW |England 2004-

**EDITORIAL WORK**

Editorial Panel: British Journal of Oral & Maxillofacial Surgery 2007-

Editorial Panel: International Journal of Maxillofacial Surgery 2007-

Editorial Panel: Indian Journal of Maxillofacial & Oral Surgery 2007-



---

**MISCELLANEOUS**

**NICE Specialist Advisor, Interventional Procedures Programme 2007-**

Designer: The "Revington Rib Cutter". Entered for the Cutler's Prize 1988, Manufactured by Leibinger

Visits to Overseas units Central Hospital Moscow: Oct/ Nov 1994  
Jan 1998 & Dec 1998  
Nitte Meenakshi Craniofacial Centre  
Mangalore, India. Jan 2005

Territorial Army  
1979 –1982  
1986 -1995  
1995- 2000  
2000-2006  
2006-  
2008-

Captain RADC (V): 203 Gen Hospital  
Major RADC (V): 217 Gen Hospital  
Major RADC (V): 374 Head & Neck FST  
Major RADC (V): 243 Field Hospital  
Lt.Col RADC(V): 243 Field Hospital  
**Clinical Director** 243 Field Hospital

**Reviewer** Commission for Health Improvement 2002-06

**Operational Deployment**

**OP Herrick** (Afghanistan) Role 3 Multinational Medical Unit Kandahar 2007

**Professional Bodies**

British Association of Oral & Maxillofacial Surgeons  
British Medical Association  
Craniofacial Society

**Medico legal Work**

Bond Solon Certificate of Expert Witness Accreditation (U. Cardiff) 2005

Approx. 80 new reports per annum